

Dissociations of cerebral cortex, subcortical and cerebral white matter volumes in autistic boys

M. R. Herbert,¹ D. A. Ziegler,¹ C. K. Deutsch,^{3,5} L. M. O'Brien,⁴ N. Lange,⁵ A. Bakardjiev,⁶ J. Hodgson,⁷ K. T. Adrien,⁸ S. Steele,⁹ N. Makris,¹ D. Kennedy^{1,2} G. J. Harris² and V. S. Caviness Jr¹

Departments of ¹Neurology and ²Radiology, Massachusetts General Hospital, Harvard Medical School, Boston, ³Shriver Center, Waltham, ⁴Department of Biostatistics, Harvard School of Public Health, Boston, ⁵Department of Psychiatry, McLean Hospital, Belmont, MA, ⁶Department of Infectious Diseases, Children's Hospital of Oakland, Oakland, CA, ⁷Pennington School, Pennington, NJ, ⁸Tufts University, Boston, MA, ⁹University of Illinois, Chicago, IL, USA

Correspondence to: Martha R. Herbert, MD, PhD, Center for Morphometric Analysis/Pediatric Neurology, Massachusetts General Hospital Room CNY149-6012, Boston, MA 02114, USA
E-mail: mherbert1@partners.org

Summary

High-functioning autistic and normal school-age boys were compared using a whole-brain morphometric profile that includes both total brain volume and volumes of all major brain regions. We performed MRI-based morphometric analysis on the brains of 17 autistic and 15 control subjects, all male with normal intelligence, aged 7–11 years. Clinical neuroradiologists judged the brains of all subjects to be clinically normal. The entire brain was segmented into cerebrum, cerebellum, brainstem and ventricles. The cerebrum was subdivided into cerebral cortex, cerebral white matter, hippocampus–amygdala, caudate nucleus, globus pallidus plus putamen, and diencephalon (thalamus plus ventral diencephalon). Volumes were derived for each region and compared between groups both before and after adjustment for variation in total brain volume. Factor analysis was then used to group brain regions based on their intercorrelations. Volumes were significantly different between groups overall; and diencephalon, cerebral white matter, cerebellum and globus pallidus–putamen were significantly larger in the autistic group. Brain volumes were not significantly different overall after

adjustment for total brain size, but this analysis approached significance and effect sizes and univariate comparisons remained notable for three regions, although not all in the same direction: cerebral white matter showed a trend towards being disproportionately larger in autistic boys, while cerebral cortex and hippocampus–amygdala showed trends toward being disproportionately smaller. Factor analysis of all brain region volumes yielded three factors, with central white matter grouping alone, and with cerebral cortex and hippocampus–amygdala grouping separately from other grey matter regions. This morphometric profile of the autistic brain suggests that there is an overall increase in brain volumes compared with controls. Additionally, results suggest that there may be differential effects driving white matter to be larger and cerebral cortex and hippocampus–amygdala to be relatively smaller in the autistic than in the typically developing brain. The cause of this apparent dissociation of cerebral cortical regions from subcortical regions and of cortical white from grey matter is unknown, and merits further investigation.

Keywords: autistic disorder; brain/growth and development; MRI; cerebral white matter; morphometry

Abbreviations: ES = effect size; GLM = general linear model; GLM-CD = general linear model for correlated data

Introduction

Autism is a highly heritable neurodevelopmental disorder affecting males more than females in a ratio of 3 : 1 or 4 : 1. It is presently diagnosed exclusively by behavioural criteria. These criteria are a triad of impaired language, impaired socialization and repetitive or ritualistic behaviours

(American Psychiatric Association, 1994). Children and adults with autism range in their cognitive competence from the highly gifted to the profoundly retarded. Whatever their level of intellectual function, they are markedly impaired in domains basic to human relationships.

Two general classes of volumetric neuroanatomic abnormality have been reported in autism, one discerning overall volumetric enlargement and the other addressing regional volume differences. In one growing set of studies, the autistic brain has been found to be somewhat larger than that of the average normal child (Piven *et al.*, 1995, 1996; Davidovitch *et al.*, 1996; Lainhart *et al.*, 1997; Bailey *et al.*, 1998; Fombonne *et al.*, 1999). In another set of studies, more focal or regionally expressed abnormalities have been described, such as increased cell density in the medial temporal regions (Kemper and Bauman, 1998), a general reduction of volume of the hippocampal–amygdala complex or other limbic structures (Bauman and Kemper, 1995; Aylward *et al.*, 1999), or diminished volume in the midline of the neocerebellar lobules and reduction in mass of the brainstem (Courchesne *et al.*, 1994b). However, with few exceptions, studies reporting pervasive enlargement have not sought more limited regional abnormalities, while studies reporting regional abnormalities have not generally considered the overall size of the brain. Thus, it is not apparent to what extent these two classes of abnormality coexist in the same brains.

We report here an MRI-based volumetric analysis of the brains of autistic children that includes both total brain volume and segmentation of major brain regions. This scope permits, within the limits of resolution of the MRI-based methodology, assessment of abnormalities in the overall size of the brain, abnormalities of the separate subdivisions of brain and forebrain, and alterations in relationships among multiple regions. In undertaking this study, we anticipated that, in keeping with prior studies, the autistic brains would be on average larger than the control brains. While it was possible that every region of the brain would be enlarged to an equal degree, we hypothesized that because of presumed underlying dysregulation of brain development in autism, not all brain regions would manifest the impact of increased brain volume in the same way. We thus hypothesized that the differences between these autistic and control brains would be both pervasive and non-uniform in their volumetric character.

Material and methods

Subjects

Quantitative volumetric analysis was performed on brain MRIs of 32 boys (17 autistic, 15 normal control) between 7 and 11 years of age. All 17 autistic boys had performance intelligence quotients (IQs) >80. All qualifying male subjects with MRIs of adequate quality were included in the analysis. Girls were excluded because the imaged sample included only two autistic girls with performance IQ >80. Autistic children were recruited between 1985 and 1988 by clinical referral or by participation in school special needs programs (Rapin, 1996). The control subjects were recruited specifically to the imaging arm of the study and were eligible if they had normal developmental history without seizures or

significant head injury, if they had normal school performance, and if their neurological examinations were normal (Filipek *et al.*, 1994; Caviness *et al.*, 1996b). English was the primary language of each child's family. Exclusion criteria included hearing or gross sensorimotor deficits, clinical evidence of progressive encephalopathy, frequent seizures or high doses of anticonvulsant drugs or psychotropic medication, the presence of potentially paramagnetic metals, and overtly evident focal brain lesions, brain atrophy or ventriculomegaly. No sedation was used for scanning. All participating institutions granted Human Subjects Committee approval, and the parents of all the study children gave written informed consent.

Diagnostic classification

The autistic subjects were recruited before they entered school as part of a larger study of children with disorders of communication (Rapin, 1996). State-of-the-art diagnostic instruments available at the time the study was conducted were used for classification, and expert clinicians confirmed all diagnoses. All children, regardless of their diagnoses, were screened using the three-part Wing Autistic Disorder Interview Checklist (Rapin, 1996), which was a parent questionnaire reviewed with an investigator or trained research assistant that covered: (i) impairment in social relatedness (nine questions); (ii) impairment in social communication (five questions); and (iii) restricted or repetitive activities (seven questions). If the child either: (i) met at least one criterion from each of three sections of the Wing Autistic Disorder Interview Checklist; or (ii) met two criteria from the first section of this interview checklist, then the child was provisionally classified as possibly autistic. Absolute criteria from the Wing Autistic Disorder Interview Checklist screen for inclusion in the autistic group comprised meeting three criteria in the first set, three in the second, and one in the third. All children were confirmed or disconfirmed in their diagnosis by a child psychiatrist blinded to the inclusion criteria, who performed a structured comprehensive evaluation with determination of diagnosis according to DSM III-R (Diagnostic and Statistical Manual of Mental Disorder, Third Edition—Revised) criteria that was current at the time of data acquisition. All subjects satisfied DSM III-R criteria for autistic disorder at the time they were diagnosed, and retained their classifications in this longitudinal study.

Image acquisition

MRI was performed on either General Electric 1.5 T Signa (Milwaukee, WI, USA) or Siemens 1.5 T (Iselin, NJ, USA) MRI systems. Images were acquired between 1989 and 1992 and included a T₁-weighted sagittal scout series, a coronal T₂-weighted sequence to rule out overt focal lesions, atrophy or ventriculomegaly, and a coronal volumetric T₁-weighted spoiled gradient echo-imaging sequence for the morphometric analysis. When performed on GE systems, the

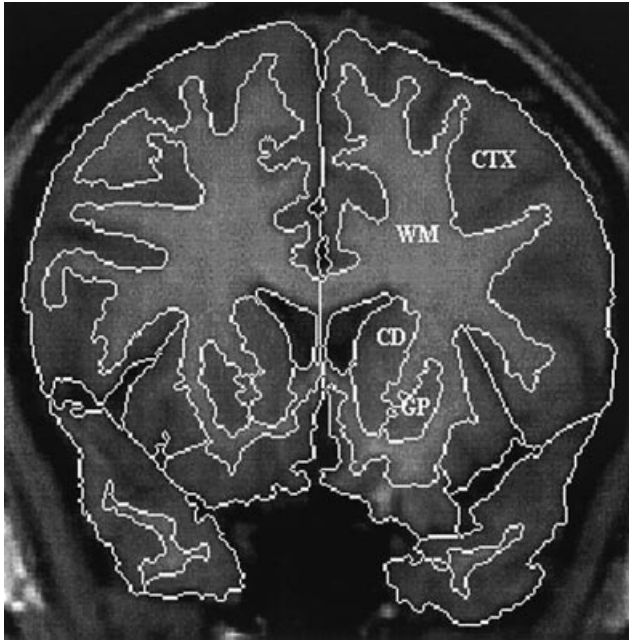


Fig. 1 Segmentation of the human brain. A coronal slice of the brain is shown here segmented into cerebral cortex (CTX), cerebral white matter (WM), caudate nucleus (CD), and globus pallidus–putamen (GP).

following parameters were used for the volumetric acquisition: pulse sequence = 3D-SPGR or 3D-CAPRY; TR = 34–50 ms; TE = 5–9 ms; flip angle = 45–50°; FOV = 24–26 cm; slice thickness = 3.0–3.1 mm; number of slices = 60 contiguous; matrix = 256 × 256; number of excitations = 1. On Siemens systems, the following parameters were used for the volumetric acquisition: pulse sequence = 3D-FLASH; TR = 40 ms; TE = 10 ms; flip angle = 40°; FOV = 30 cm; slice thickness = 3.1 mm; number of slices = 60 contiguous; matrix = 256 × 256; number of excitations = 1. Images on the two systems were found to be comparable for quantitative segmentation analysis (Filipek *et al.*, 1991b). To ensure that the use of multiple imaging systems was not a confounding factor in this study, scanner type was controlled for in all statistical analyses.

Image analysis

Image positional normalization

Imaging data was analysed on Sun Microsystems, Inc. (Mountainview, CA, USA) workstations. The initial image data set was normalized with respect to Talairach stereotactic space, wherein the anterior–posterior commissure line specifies the *x*-axis, a vertical rising from the *x*-axis through the interhemispheric fissure represents the *y*-axis, and a transverse orthogonal line with respect to *x* and *y* coordinates represents the *z*-axis (Talairach and Tournoux, 1988). Coronal, axial and sagittal planes used in the morphometric algorithms were then derived computationally (Kennedy

et al., 1994), minimizing the need for precise uniformity of head position at the time of imaging. The reformatted images are interpolated using a tri-linear scheme. Because the coronal view was both the acquisition and the target orientation of the reformatting process, only relatively small (a few degrees) rotations in each axis were typically necessary, minimizing the effects of spatial blurring along the ‘long axis’ of the acquisition voxels (Filipek *et al.*, 1991a). In addition, the intensity distributions of the original and normalized images are conserved in the reformatting process, rendering the intensity-based segmentation procedures used in this analysis relatively insensitive to the normalization process.

Neuroanatomic segmentation was performed using semi-automated algorithms based upon intensity contour mapping and differential intensity contour algorithms that have been previously described (Fig. 1) (Filipek *et al.*, 1989, 1994; Kennedy *et al.*, 1994). Segmentation was performed on coronal images, and divided the brain into grey matter and white matter regions. Cerebral cortex–white matter distinctions were accomplished in a semi-automated fashion, while deep grey nuclei were delineated manually. The normative grey and white matter volumes achieved by this method are consistent with many other published volumes in the literature (including but not limited to: Castellanos *et al.*, 1996; Giedd *et al.*, 1996; Schnack *et al.*, 2001). Because it is derived systematically, the grey–white separation line will be consistent even in diagnostic populations where there may be an alteration in grey and white matter intensities.

The total brain was partitioned into its principal regions: cerebrum, brainstem, cerebellum and ventricular system. The cerebrum was further segmented into its principal grey matter structures and total cerebral white matter (Tables 1 and 2) (Filipek *et al.*, 1994). Segmentation of grey from white matter in cerebellum or brainstem could not be performed reliably in this data set. The total number of voxels in each brain region determined its volume.

Data analysis

Statistical computations were performed using SPSS (SPSS Inc., Chicago, IL, USA) and SAS (SAS Institute Inc., Cary, NC, USA) statistical analysis software. Graphics were generated by Excel (Microsoft, Redmond, WA, USA). A univariate general linear model (GLM) (Darlington, 1990) was used to test for differences in total brain volume between autistic and control children, controlling for age and scanner type. Previously published analyses of this control sample, but also including female subjects, have demonstrated no significant effect of age upon brain volume for various brain regions (Caviness *et al.*, 1996a, b). However, to ensure that any significant differences were not the result of an undetected age effect, age was still included in all analyses as a covariate.

Multivariate GLMs for correlated data (GLM-CD) (Cnaan *et al.*, 1997), which rely on maximum likelihood estimation,

Table 1 Descriptive statistics for unadjusted volumes

Brain region	Autistic group		Control group		Between group comparisons	
	Mean brain volume (cm ³)	SD	Mean brain volume (cm ³)	SD	ES	<i>P</i> value
Total brain volume	1453.96	136.98	1367.44	106.17	0.670	0.077
Diencephalon	23.34	2.49	21.16	1.18	0.969	0.004
Cerebral white matter	441.04	59.14	383.94	52.24	0.917	0.010
Cerebellum	155.03	12.31	144.88	8.60	0.864	0.011
Globus pallidus–putamen	16.47	1.91	15.06	1.17	0.810	0.028
Brainstem	22.94	2.72	21.30	2.14	0.642	0.057
Caudate	10.92	1.66	10.05	1.20	0.581	0.134
Cerebral cortex	755.30	81.38	739.70	76.62	0.199	0.675
Hippocampus–amygdala	14.75	1.98	14.98	1.63	–0.129	0.697

Overall *F*-test of group differences was obtained using multivariate GLM for correlated data, controlling for age and scanner [$F(8,31) = 2.52, P = 0.031$]. *P* values refer to univariate tests of total brain and regional volume differences. ES = (autistic mean – control mean)/pooled SD.

Table 2 Descriptive statistics for adjusted volumes

Brain region	Autistic group		Control group		Between group comparisons	
	Mean brain volume (cm ³)	SD	Mean brain volume (cm ³)	SD	ES	<i>P</i> value
Cerebral white matter	30.29	2.52	28.05	2.91	0.77	0.027
Cerebral cortex	51.94	2.50	54.05	2.85	–0.74	0.026
Hippocampus–amygdala	1.02	0.12	1.10	0.11	–0.68	0.051
Diencephalon	1.61	0.13	1.55	0.10	0.46	0.15
Globus pallidus–putamen	1.13	0.09	1.11	0.10	0.29	0.47
Brainstem	1.58	0.14	1.56	0.17	0.11	0.63
Caudate	0.75	0.10	0.73	0.07	0.19	0.67
Cerebellum	10.71	0.84	10.65	0.97	0.07	0.7

Regional brain volumes as percentages of total brain volume. Overall *F*-test of group differences was obtained using multivariate GLM for correlated data, controlling for total brain volume, age and scanner [$F(8,31) = 1.93, P = 0.091$]. ES = (adjusted autistic mean – adjusted control mean)/pooled SD. Significance levels were derived from univariate GLMs, covarying for total brain volume, age and scanner.

were used to test the composite, or omnibus, null hypothesis of no difference overall among brain volumes between autistic and control subjects. This model was appropriate given that the data were found to be approximately normally distributed and there were large correlations between some brain regions. The GLM-CD allows for the presence of significant correlations in dependent variables and accounts for any error this might yield in the estimation of standard errors associated with parameter estimates.

A primary multivariate GLM-CD was run on all unadjusted regional brain volumes to test for an effect of diagnosis, while controlling for possible effects of age and scanner. Volumes for the following brain regions were included as dependent variables: brainstem, cerebellum, cerebral cortex, cerebral white matter, hippocampus–amygdala, caudate, globus pallidum–putamen and diencephalon. *Post hoc* pairwise univariate comparisons between groups were performed for each region using standard univariate GLMs, while controlling for any effects of age

and scanner. To test for differences in brain volumes while adjusting for possible group differences in overall brain volume, an additional multivariate GLM-CD was performed, including total brain volume, as well as age and scanner, as covariates. Finally, maximum likelihood-based factor analysis (Tabachnick and Fidell, 2001) was used to estimate the amount of variance in regional brain volumes that might be accounted for by differences in overall brain size.

Effect sizes (ES) (Cohen, 1988) of the differences between groups in terms of both unadjusted and adjusted volumes were estimated for each region as follows: (mean autistic volume – mean control volume)/pooled SD of autistic and control volumes. Thus, a positive value reflects a larger volume in autistic children, whereas negative values indicate larger volumes in controls. Effect size estimates provide useful standardized measures of the magnitude of differences between groups, since they are unaffected by sample size and are comparable across studies.

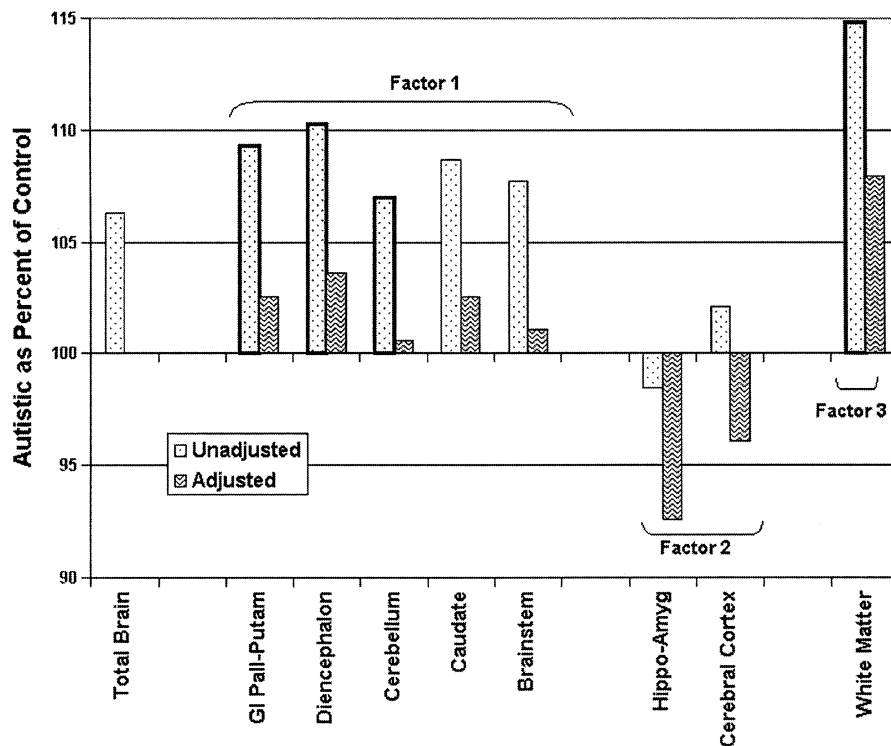


Fig. 2 Autistic as percent of control volume. Percentages were calculated as: (mean autistic volume)/(mean control volume) \times 100. Values >100 indicate region is larger in the autistic group; values <100 represent larger volumes in the control group. Unadjusted volume comparisons are indicated by stippled bars; adjusted volume comparisons by hatched bars. Heavily outlined bars indicate that the autistic volume is significantly different from the control volume ($P < 0.05$). Brain regions are organized according to their primary factor analytic loadings, which are indicated on the chart.

Results

Unadjusted volumes

A multivariate GLM-CD showed a significant difference between autistic and control children in terms of regional volumes when considering brainstem, cerebellum, hippocampus–amygdala, globus pallidus–putamen, caudate, diencephalon, cerebral white matter and cerebral cortex simultaneously (Fig. 2), and while controlling for effects of age and scanner [$F(8,31) = 2.52$, $P = 0.03$]. Following the significant GLM-CD, univariate comparisons were made for each regional volume between the autistic and control groups using a standard GLM with effects of age and scanner controlled. The resultant significance levels, descriptive statistics and ESs for these comparisons are shown in Table 1 (ordered in terms of decreasing absolute ESs). In all cases, except hippocampus–amygdala, mean autistic volumes were greater than controls. Diencephalon showed the greatest effect, with a mean autistic volume of 23.3 cm^3 as compared with 21.2 cm^3 in controls [$F(1,28) = 9.8$, $P = 0.004$]. Cerebral white matter showed the next largest effect, being 441.04 cm^3 in autistics and only 383.94 cm^3 in controls [$F(1,28) = 7.7$, $P = 0.009$]. Cerebellar volume was 155.0 cm^3 for the autistic group and 144.9 cm^3 for controls [$F(1,28) = 7.8$, $P = 0.009$] and globus pallidus–putamen volume was

16.5 cm^3 for the autistic group and 15.1 cm^3 for controls [$F(1,28) = 5.4$, $P = 0.028$]. Differences in brainstem volumes approached significance [$F(1,28) = 3.95$, $P = 0.057$], with a mean of 22.9 cm^3 in autistic children as compared with 21.3 cm^3 in controls. A univariate GLM showed that the average total brain volume in these autistic children (1454 cm^3) was modestly larger than that of the control series (1367 cm^3), but the difference did not reach statistical significance, while controlling for age and scanner [$F(1, 31) = 3.4$, $P = 0.08$], although the ES was 0.67. It is also worth noting that ESs (see Table 1) for those regions that showed significant differences ranged from 0.81 to 0.97, which are considered to be large (Cohen, 1988).

Adjusted volumes

A secondary GLM-CD was used to assess differences in regional brain volumes between autistic and control children, controlling for total brain size, age and scanner (Fig. 2). A significant difference between groups was not discerned [$F(8,31) = 1.93$, $P = 0.09$]. However, given that this test approached significance, univariate statistics are reported in Table 2, along with adjusted means, SDs and ESs, in order to provide a complete statistical profile of all brain regions

Table 3 Factor loading matrix

Brain region	Factor		
	1	2	3
Globus pallidus–putamen	0.95	–	–
Diencephalon	0.70	–	–
Cerebellum	0.69	–	–
Caudate	0.64	–	–
Brainstem	0.61	–	–
Cerebral cortex	–	0.90	–
Hippocampus–amygdala	–	0.71	–
Cerebral white matter	–	–	0.85
Percent of variance:	38.78	17.31	15.05

Loadings of brain regions on each of three factors and percentage of total variance accounted for by each factor. Loadings <0.5 are omitted.

examined. In particular, three regions showed significant univariate differences between the autistic and control boys and moderate to large ESs: these include the cerebral white matter adjusted volume increase in autistic boys [$F(1,28) = 5.47, P = 0.03; ES = 0.77$], and the adjusted volume decreases in the autistic group for cerebral cortex [$F(1,28) = 5.49, P = 0.03; ES = -0.74$] and hippocampus–amygdala [$F(1,28) = 4.15, P = 0.05; ES = -0.68$].

Factor analysis

Factor analytic methods were used to assess the underlying importance of brain size in accounting for the variance in regional brain volumes, considering autistic and control children together. Maximum likelihood estimation with varimax (orthogonal) rotation was used to extract three factors from the correlations between the eight regional brain volumes (Table 3). A three-factor model, accounting for 71.1% of the shared variance in brain volumes, was deemed most parsimonious with the data; the third factor was found to account for a significant portion of the total variance beyond that found for a two-factor model; and a model with more than three factors failed to converge. Using a cut-off of 0.5 for inclusion of a variable in the interpretation of each factor, simple structure was achieved, with each variable loading primarily on only one factor (see Table 3 for factor loadings). Oblique rotation did not have a discernable effect on the pattern of factor loadings, so orthogonal rotation was chosen. The variables that loaded on the first factor, accounting for 38.8% of the total variance, were cerebellum, brainstem, caudate, globus pallidus–putamen and diencephalon. Cerebral cortex and hippocampus–amygdala loaded on the second factor and accounted for 17.3% of variance; cerebral white matter was the only variable loading on the last factor and accounted for 15.0% of variance. Cerebral cortex and cerebral white matter were also moderately associated with the first factor, but showed much higher loadings on subsequent factors.

Discussion

This morphometric profile of a set of brains of high-functioning autistic and control school-aged boys revealed a set of systemic differences between the two diagnostic samples, where three groupings of brain structures all showed distinctive volumetric patterns. One grouping, which included diencephalon, caudate, globus pallidus–putamen, cerebellum and brainstem, contained structures that, with the exception of the caudate, displayed significantly larger volumes in the autistic group, but that showed similar proportions in both groups. The second grouping, which included cerebral cortex and hippocampus–amygdala, had similar volumes between groups but had ESs and univariate pairwise P values suggesting possible smaller adjusted volumes in the autistic group. The third grouping, which included only cerebral white matter, was both larger in volume and also had an ES and univariate pairwise P value that suggested larger adjusted volume in the autistic group. These differences in volumes and proportions suggest that autistic brains have non-uniform differences in scaling as compared with controls: it appears that the first group of regions is scaled comparably to controls, the second is scaled somewhat smaller and the third is scaled larger. This division into three groups with distinctive proportions and scaling is supported by our factor analysis, while the volumetric characterizations of each group are derived from direction of volume changes in unadjusted and adjusted brain volumes.

These widespread non-uniform differences in scaling, discerned for the first time in this whole-brain volumetric study, are intriguing. While our sample size is small, the significant findings in unadjusted volumes, in combination with several univariate pairwise P values <0.05 and medium to large ESs (Cohen, 1988) in adjusted volumes, suggest that further exploration in larger samples of the possibility of non-uniformity of volumetric scaling in autism is warranted.

The significant increases in multiple unadjusted regional volumes takes place in this sample in the setting of a modest increase in total brain size. Certainly, a growing number of studies have documented an increase in brain volume in autistic subjects, using *post mortem* measures of brain weight (Bauman and Kemper, 1985; Bailey *et al.*, 1998; Kemper and Bauman, 1998), measures of head circumference during life (Bailey *et al.*, 1993; Davidovitch *et al.*, 1996; Rapin, 1996; Woodhouse *et al.*, 1996; Lainhart *et al.*, 1997; Fombonne, 1999; Aylward *et al.*, 2002), and *in vivo* MRI volumetric studies (Piven *et al.*, 1995, 1996; Courchesne *et al.*, 2001; Aylward *et al.*, 2002; Sparks *et al.*, 2002). In the current study, although the mean total brain volume of autistic children in this series was modestly larger than that of the normal control children with whom they were compared, this difference approached but did not achieve significance. This may be a consequence of the sample size analysed presently, which is smaller than those reported in several previous MRI-based volumetric studies. It is most likely not due to differences in methodology between the current and previous

studies, as the overall and regional brain volumes for this control group are consistent with previously published normative brain volumes for children of similar age (Castellanos *et al.*, 1996; Reiss *et al.*, 1996; Giedd *et al.*, 1999; Courchesne *et al.*, 2001). It is quite possible that the increased white matter volume is counterbalanced by the apparent relative decrease in cerebral cortical grey matter volume, yielding an overall volume increase that is only modest. In some other studies discerning overall volume increase (e.g. Courchesne, 2001) a reduction in cerebral cortex volume comparable to that reported here was not found.

Non-uniform volumetric differences

The coexistence in our findings of an only modest increase in overall brain size with several much more robust regional volumetric differences—as well several regions whose volumes are indistinguishable from controls—suggests that either multiple processes or multiple vulnerabilities are operative. With regard to the regions grouped in factor one, the larger volume but similar scaling in the autistic as compared with the control group suggests that the first factor might be considered ‘brain size’, where the differences detected between autistic and control children in these regions, prior to adjustment, are most likely due to the distributed effects of the marginally increased overall brain volume seen in the autistic sample. Consistent with this interpretation, previous factor analytic studies of brain volumes across mammalian species have found that a primary ‘brain size’ factor accounts for most of the variance seen in volumes of all non-limbic brain regions (Finlay and Darlington, 1995; Darlington *et al.*, 1999). By the same token, the three regions that had large between-group ESs and univariate *P* values ≤ 0.05 following adjustment for total brain size (i.e. cerebral white matter, cerebral cortex and hippocampus–amygdala) are the same regions that loaded separately as factors 2 and 3 in the factor analysis, suggesting that the variability in these regions is primarily accounted for by different underlying forces, and that ‘brain size’ alone may not sufficiently account for the volume differences in these latter three regions.

From a neuroanatomical point of view, the inter-group differences are systemic, but not modular; that is, we see an increase in volume that is widespread and not a purely local phenomenon. Within the overall volume increase, we see a series of regionally or subdivision-based dissociations. One dissociation is between subcortical, axial structures (as well as cerebellum) and cortical structures (cerebral cortex and hippocampus–amygdala); another dissociation is between grey matter (particularly cortex) and cerebral white matter.

Volumetric precedents

At the level of region of interest studies, there are precedents for several components of these findings, albeit not fully

consistent regarding either methodology or results. Some studies have found reduced proportional, but not absolute, volume of the hippocampus–amygdala complex, (Aylward *et al.*, 1999; Pierce *et al.*, 2001), supporting the trend noted presently although other investigations have not yielded the same result (Abell *et al.*, 1999; Haznedar *et al.*, 2000; Howard *et al.*, 2000; Sparks *et al.*, 2002). Increased caudate volume (Sears *et al.*, 1999), while not replicated here, was found to be proportional to total brain volume, and may be masked in this sample by the modest extent to which total brain volume was increased in this autistic sample. However, a recent study found no differences in caudate volume between adults with Asperger’s syndrome and controls (McAlonen *et al.*, 2002). While there are, to our knowledge, no prior volumetric studies of diencephalic nuclei in autism, others have reported biochemical and activation abnormalities of the thalamocortical pathways in children with autism (Horwitz *et al.*, 1988; Chugani *et al.*, 1997; Muller *et al.*, 1998), thus indirectly supporting the current findings. Our cerebellar volume measure is not comparable to many prior measures of cerebellar vermis area (Courchesne *et al.*, 1988; Holttum *et al.*, 1992; Courchesne *et al.*, 1994a), but is consistent with other findings of increased overall cerebellar size (Piven *et al.*, 1997; Sparks *et al.*, 2002). With regard to cerebral cortex, voxel-based morphometric measures of a number of cortical regions found increases in some regions and decreases in others, but did not yield an overall volumetric measure (Abell *et al.*, 1999). Others have found increased temporal, occipital and parietal lobe volumes in males with autism, accompanied by an increase in total brain volume (Piven *et al.*, 1996). However, these cortical volumes were not analysed after adjustment for this increase in overall brain volume, and the age range of these subjects was much greater than the range in the present study. Furthermore, very young (2–3 years) children with autism have also shown increased cerebral grey matter volume (Courchesne *et al.*, 2001), but again without adjustment for total brain volume. In a second, older sample (12–16 years), no difference in cerebral grey matter volume was detected between autistic and control children (Courchesne *et al.*, 2001). Hardan *et al.* (2001) reported an increase in cerebral volume, relative to intracranial volume, in autistic subjects, but this measure combined grey and white matter and the subjects were older than those included in our sample.

Several groups have recently reported increased white matter volume in autism. We have reported the current findings and a preliminary replication in an independent sample in abstract form (Herbert *et al.*, 2001). In another report, an increase in white matter volume in autism is localized to the temporal-parietal region (Cody *et al.*, 2001). The main precedent for our finding of disproportionately enlarged white matter is a recent cross-sectional study (Courchesne *et al.*, 2001), in which a younger group of autistic patients manifests a somewhat greater enlargement than in our sample not only of cerebral white matter, but of cerebellar white matter as well, and also of cerebral but not

cerebellar grey matter (our study does not address grey/white distinctions in brainstem or cerebellum, although our increased overall cerebellar volume could conceivably be related to a similar cerebellar white matter volume increase). Autistic 2- and 3-year-olds in the study by Courchesne *et al.* (2001) had 18% more cerebral white matter than their normal controls, whereas the adolescent autistic subjects had less white matter than controls. In the present study, 7- to 11-year-old autistic children displayed 15% more white matter than controls—an amount in between those noted in younger and older groups. Since the autistic subjects examined in the current study were midway in age between the adolescents and small children in the study by Courchesne and colleagues, the differences in white matter among these three age groups suggests a possible downward trajectory of cerebral white matter growth rate compared with controls as the children age (Courchesne *et al.*, 2001). This would be consistent with recently reported data suggesting an overgrowth of total brain volume in childhood followed by a later normalization in autistic subjects as compared with controls (Minshew *et al.*, 2001; Aylward *et al.*, 2002).

Neurobiological and cognitive implications

A pertinent and potentially critical observation is that head circumference in autistic children tends to be normal at birth, with increases occurring only in the first several years of life (Lainhart *et al.*, 1997; Courchesne *et al.*, 2001). In this interval we move beyond the principal period of axon pruning, while the glial population continues to proliferate and white matter mass is still expanding (Yakovlev and Lecours, 1967; Brody *et al.*, 1987; Kinney *et al.*, 1988). It is thus possible that the larger white matter volume might be a result of excessive glial proliferation, although it could also be accounted for by abnormalities of myelin maturation or composition. Immunological factors have been implicated in autism (Singh *et al.*, 1993; Korvatska *et al.*, 2002), and these may conceivably play a role in the cell biological mechanisms underlying volumetric anomalies, albeit by other than typical focal inflammatory mechanisms. In any event, the phenomenon encourages an in-depth developmental analysis of the cytology and biochemistry of white matter in autism.

The dissociation between cortex and white matter is particularly intriguing. The fact that cerebral white matter is larger while cortical regions do not differ, but show a trend toward being relatively smaller in the autistic sample following adjustment for total brain volume, suggests that there may be an alteration in the relationship between cortical structures and axonal connections. It is conceivable that this alteration is related to recently reported changes in minicolumnar structure in autistic cerebral cortex (Casanova *et al.*, 2002), in that the more compacted cortical columns could yield volumetric reduction, while axonal number might remain proportional to the unchanged cell number (Casanova *et al.*, 2002). Rather than being a direct expression of primary pathophysiological mechanisms, the relative

increase in white matter might conceivably occur in reaction to widespread neural systems malfunction, where excessive but disordered axonal activity could lead to an increase in oligodendrocyte population (Barres and Raff, 1999). The altered relationship between volumes of regions that one would assume should co-vary (Zhang and Sejnowski, 2000) suggests compromise in optimality of connectivity in these autistic brains.

Our review of the neurological literature has not revealed a precedent for the type of abnormality we describe here. The pathophysiology appears to occur prenatally and into the first several years of life. But it is not destructive, degenerative or clearly focal, and it leads to volume increase rather than loss. Classical pathological-behavioural correlation is challenged by the diversity of both aetiologies associated with the disorder and phenotypic features; even the three cardinal features of socialization, language and behavioural abnormalities are hard to encompass in a single focal model. The fact that these features are so often found in the setting of more widely ranging abnormalities that may include attentional and impulse control disturbances, motor clumsiness, intercurrent seizures, and even immunological and gastrointestinal abnormalities further challenges focal approaches, and suggests a more systemic insult.

The morphological profile we have discerned challenges us to explain the pathophysiology of the pervasive and non-modular but also non-uniform volumetric differences, but also to address the relationship of this neurobiological abnormality to the behavioural phenotype. Pathophysiologically, a process yielding these macroscopic consequences is more likely to target neural systems than specific regions, and even more likely to act pervasively but with differentiated impact due to regionally varying thresholds of vulnerability (Caviness, 2001). Such classes of insults with non-modular but non-uniform effects have precedents in studies of *in utero* drug exposure (Levitt, 1998), infection (Hornig *et al.*, 1999; Pletnikov *et al.*, 2002) and of generalized metabolic disturbances that selectively disable particular circuits (Calabresi *et al.*, 2000).

Even a pervasive uniform tissue effect might have graded or differential functional consequences because of different thresholds for functional expression. Some such type of pervasive insult may be consistent with several functional hypotheses, suggesting that underlying the spectrum of behavioural and cognitive features in autism is a generalized deficit. Candidate models have included weak central coherence (Frith and Happe, 1994), a deficit in complex processing (Minshew *et al.*, 1997), and impaired temporal binding or neural integration (Nunez, 2000; Brock *et al.*, 2002). Such generalized impairments would be expected to derive from more widely distributed rather than regional or focal neural insults. Both the enlarged white matter and the altered volumetric relationships among regions with non-uniform volumetric changes we report here could preferentially disable cognitive functions more dependent on complex connectivity.

Conclusion

This whole-brain morphometric profile reveals pervasive but non-uniform volumetric changes in autistic boys, in the setting of a trend toward overall brain enlargement. The dissociation of disproportionate enlargement of cerebral white matter from relatively smaller cortex and hippocampus–amygdala, and proportional subcortical grey matter, brainstem and cerebellar volumes suggests that systemic changes are at work. We are pursuing more finely grained elaboration of the present neuroanatomical findings through parcellation of this study's units of analysis into cortical, subcortical and white matter subregions. Further studies are also needed on larger samples, including older and younger subjects than the ones here described, and on female subjects as well, given the non-uniformly scaled character of regional volume changes during development and between sexes (Caviness *et al.*, 1996b; Giedd *et al.*, 1996; Reiss *et al.*, 1996). Longitudinal studies would allow much greater insight into the different trajectories among regions of volume changes over time. Insights garnered from these efforts may help to refine the implications of this autistic morphometric profile for behavioural and cellular investigations. The variability of findings in autism morphometric studies highlights a further issue from the point of view of developmental cognitive neuroscience: we remain challenged by the question of what unites a diverse set of neuroanatomical abnormalities into a syndrome with a common behavioural phenotype.

Acknowledgements

We would like to thank Jill Goldstein, Larry Seidman, and Isabelle Rapin for their thoughtful comments on this manuscript. This work was supported in part by NINDS multi-institutional Program Project grant NS 20489; the Cure Autism Now Foundation; NIH grants NS02126, NS27950, DA09467, NIDCD P01-DC03610 and NS37483; NIH grants NS34189 and MH57180 as part of the Human Brain Project; and grants from the Fairway Trust and the Giovanni Armenise-Harvard Foundation for Advanced Scientific Research. The following investigators participated in subject recruitment and testing and in behavioural data analysis: D. A. Allen, D. M. Aram, R. David, M. Dunn, D. Fein, C. Feinstein, P. Filipek, J. Flax, N. Hall, R. Morris, I. Rapin, L. Wainwright, L. Waterhouse and B. C. Wilson.

References

Abell F, Krams M, Ashburner J, Passingham R, Friston K, Frackowiak R, et al. The neuroanatomy of autism: a voxel-based whole brain analysis of structural scans. *Neuroreport* 1999; 10: 1647–51.

American Psychiatric Association. Diagnostic and statistical manual of mental disorders. (DSM-IV). 4th ed. Washington (DC): American Psychiatric Association; 1994.

Aylward EH, Minshew NJ, Goldstein G, Honeycutt NA, Augustine AM, Yates KO, et al. MRI volumes of amygdala and hippocampus in non-mentally retarded autistic adolescents and adults. *Neurology* 1999; 53: 2145–50.

Aylward EH, Minshew NJ, Field K, Sparks BF, Singh N. Effects of age on brain volume and head circumference in autism. *Neurology* 2002; 59: 175–83.

Bailey A, Luthert P, Bolton P, LeCouteur A, Rutter M, Harding B. Autism and megalencephaly. *Lancet* 1993; 341: 1225–6.

Bailey A, Luthert P, Dean A, Harding B, Janota I, Montgomery M, et al. A clinicopathological study of autism. *Brain* 1998; 121: 889–905.

Barres BA, Raff MC. Axonal control of oligodendrocyte development. *J Cell Biol* 1999; 147: 1123–8.

Bauman M, Kemper TL. Histoanatomic observations of the brain in early infantile autism. *Neurology* 1985; 35: 866–74.

Bauman M, Kemper T. Neuroanatomical observations of the brain in autism. *Adv Biol Psychiatry* 1995; 1: 1–26.

Brock J, Brown CC, Boucher J, Rippon G. The temporal binding deficit hypothesis of autism. *Dev Psychopathol* 2002; 14: 209–24.

Brody BA, Kinney HC, Kloman AS, Gilles FH. Sequence of central nervous system myelination in human infancy. 1. An autopsy study of myelination. *J Neuropathol Exp Neurol* 1987; 46: 283–301.

Calabresi P, Centonze D, Bernardi G. Cellular factors controlling neuronal vulnerability in the brain: a lesson from the striatum. *Neurology* 2000; 55: 1249–55.

Casanova MF, Buxhoeveden DP, Switala AE, Roy E. Minicolumnar pathology in autism. *Neurology* 2002; 58: 428–32.

Castellanos FX, Giedd JN, Marsh WL, Hamburger SD, Vaituzis AC, Dickstein DP, et al. Quantitative brain magnetic resonance imaging in attention-deficit hyperactivity disorder. *Arch Gen Psychiatry* 1996; 53: 607–16.

Caviness VS. Research strategies in autism: a story with two sides. *Curr Opin Neurol* 2001; 14: 141–3.

Caviness VS, Kennedy DN, Bates JF, Makris N. The developing human brain: a morphometric profile. In: Thatcher RW, Lyon GR, Rumsey J, Krasnegor N, editors. *Developmental neuroimaging*. San Diego (CA): Academic Press; 1996a. p. 3–14.

Caviness VS, Kennedy DN, Richelme C, Rademacher J, Filipek PA. The human brain age 7–11 years: a volumetric analysis based on magnetic resonance images. *Cereb Cortex* 1996b; 6: 726–36.

Chugani DC, Muzik O, Rothermel R, Behen M, Chakraborty P, Mangner T, et al. Altered serotonin synthesis in the dentatohalamocortical pathway in autistic boys. *Ann Neurol* 1997; 42: 666–9.

Cnaan A, Laird NM, Slasor P. Using the general linear mixed model to analyse unbalanced repeated measures and longitudinal data. *Stat Med* 1997; 16: 2349–80.

Cody A, Keyes-Elstein L, Piven J. Gray and white matter volume on MRI in autism [abstract]. *IMFAR* 2001; Program No. B-26.

Cohen J. *Statistical power analysis for the behavioral sciences*. 2nd ed. Hillsdale (NJ): Lawrence Erlbaum; 1988.

- Courchesne E, Yeung-Courchesne R, Press GA, Hesselink JR, Jernigan TL. Hypoplasia of cerebellar vermal lobules VI and VII in autism. *New Engl J Med* 1988; 318: 1349–54.
- Courchesne E, Saitoh O, Yeung-Courchesne R, Press GA, Lincoln AJ, Haas RH, et al. Abnormality of cerebellar vermal lobules VI and VII in patients with infantile autism: identification of hypoplastic and hyperplastic subgroups with MR imaging. *AJR Am J Roentgenol* 1994a; 162: 123–30.
- Courchesne E, Townsend J, Saitoh O. The brain in infantile autism: posterior fossa structures are abnormal. *Neurology* 1994b; 44: 214–23.
- Courchesne E, Karns CM, Davis HR, Ziccardi R, Carper RA, Tigue ZD, et al. Unusual brain growth patterns in early life in patients with autistic disorder: an MRI study. *Neurology* 2001; 57: 245–54.
- Darlington RB. Regression and linear models. New York (NY): McGraw-Hill; 1990.
- Darlington RB, Dunlop SA, Finlay BL. Neural development in metatherian and eutherian mammals: variation and constraint. *J Comp Neurol* 1999; 411: 359–68.
- Davidovitch M, Patterson B, Gartside P. Head circumference measurements in children with autism. *J Child Neurol* 1996; 11: 389–93.
- Filipek PA, Kennedy DN, Caviness VS, Rossnick SL, Spraggins TA, Starewicz PM. Magnetic resonance imaging-based brain morphometry: development and application to normal subjects. *Ann Neurol* 1989; 25: 61–7.
- Filipek P, Kennedy DN, Caviness VS. Volumetric analyses of central nervous system neoplasm based on MRI. *Pediatr Neurol* 1991a; 7: 347–51.
- Filipek PA, Kennedy D, Pitcher D, Caviness VS. MRI-based morphometric analyses: reproducibility across multiple systems and pulse sequences over time on a single volunteer. *Proc Soc Magn Reson Med* 1991b; 10: 753.
- Filipek PA, Richelme C, Kennedy DN, Rademacher J, Petcher DA, Zidel S, et al. Morphometric analysis of the brain in developmental language disorders and autism [abstract]. *Ann Neurol* 1992; 32: 475.
- Filipek PA, Richelme C, Kennedy DN, Caviness VS. The young adult human brain: an MRI-based morphometric analysis. *Cereb Cortex* 1994; 4: 344–60.
- Finlay BL, Darlington RB. Linked regularities in the development and evolution of mammalian brains. *Science* 1995; 268: 1578–84.
- Fombonne E, Roge B, Claverie J, County S, Fremolle J. Microcephaly and macrocephaly in autism. *J Autism Dev Disord* 1999; 29: 113–9.
- Frith U, Happe F. Autism: beyond the ‘theory of mind’. *Cognition* 1994; 50: 115–32.
- Giedd JN, Snell JW, Lange N, Rajapakse JC, Casey BJ, Kozuch PL, et al. Quantitative magnetic resonance imaging of human brain development: ages 4–18. *Cereb Cortex* 1996; 6: 551–60.
- Giedd JN, Blumenthal J, Jeffries NO, Castellanos FX, Liu H, Zijdenbos A, et al. Brain development during childhood and adolescence: a longitudinal MRI study. *Nat Neurosci* 1999; 2: 861–3.
- Hardan AY, Minshew NJ, Mallikarjuhn M, Keshavan MS. Brain volume in autism. *J Child Neurol* 2001; 16: 421–4.
- Haznedar MM, Buchsbaum MS, Wei TC, Hof PR, Cartwright C, Bienstock CA, et al. Limbic circuitry in patients with autism spectrum disorders studied with positron emission tomography and magnetic resonance imaging. *Am J Psychiatry* 2000; 157: 1994–2001.
- Herbert M, Hodge S, Steele S, Adrien K, Makris N, Kennedy D, et al. Large brains with increased white matter volume in two groups of high-functioning autistic boys [abstract]. *IMFAR 2001; Program No. B-26*.
- Holttum JR, Minshew NJ, Sanders RS, Phillips NE. Magnetic resonance imaging of the posterior fossa in autism. *Biol Psychiatry* 1992; 32: 1091–101.
- Hornig M, Weissenbock H, Horscroft N, Lipkin WI. An infection-based model of neurodevelopmental damage. *Proc Natl Acad Sci USA* 1999; 96: 12102–7.
- Horwitz B, Rumsey JM, Grady CL, Rapoport SI. The cerebral metabolic landscape in autism. Intercorrelations of regional glucose utilization. *Arch Neurol* 1988; 45: 749–55.
- Howard MA, Cowell PE, Boucher J, Broks P, Mayes A, Farrant A, et al. Convergent neuroanatomical and behavioural evidence of an amygdala hypothesis of autism. *Neuroreport* 2000; 11: 2931–5.
- Kemper TL, Bauman M. Neuropathology of infantile autism. *J Neuropathol Exp Neurol* 1998; 57: 645–52.
- Kennedy DN, Meyer JM, Filipek PA, Caviness VS. MRI-based topographic segmentation. In: Thatcher RW, Hallett M, Zeffiro T, John ER, Huerta M, editors. *Functional neuroimaging: technical foundations*. San Diego (CA): Academic Press; 1994. p. 201–8.
- Kinney HC, Brody BA, Kloman AS, Gilles FH. Sequence of central nervous system myelination in human infancy. II. Patterns of myelination in autopsied infants. *J Neuropathol Exp Neurol* 1988; 47: 217–34.
- Korvatska E, Van de Water J, Anders TF, Gershwin ME. Genetic and immunologic considerations in autism. *Neurobiol Dis* 2002; 9: 107–25.
- Lainhart JE, Piven J, Wzorek M, Landa R, Santangelo SL, Coon H, et al. Macrocephaly in children and adults with autism. *J Am Acad Child Adolesc Psychiatry* 1997; 36: 282–90.
- Levitt P. Prenatal effects of drugs of abuse on brain development. *Drug Alcohol Depend* 1998; 51: 109–25.
- McAlonen GM, Daly E, Kumari V, Critchley HD, van Amelsvoort T, Suckling J, et al. Brain anatomy and sensorimotor gating in asperger’s syndrome. *Brain* 2002; 127: 1594–1606.
- Minshew J, Goldstein G, Siegel D. Neuropsychologic functioning in autism: Profile of a complex informational processing disorder. *J Int Neuropsychol Soc* 1997; 3: 303–16.
- Minshew NJ, Aylward EH, Field K, Sparks BF, Singh N. Age-related changes in brain volume and head circumference in autism [abstract]. *Soc Neurosci Abstr* 2001; 27.

- Muller RA, Chugani DC, Behen ME, Rothermel RD, Muzik O, Chakraborty PK, et al. Impairment of dentato-thalamo-cortical pathway in autistic men: language activation data from positron emission tomography. *Neurosci Lett* 1998; 245: 1–4.
- Nunez PL. Toward a quantitative description of large-scale neocortical dynamic function and EEG. *Behav Brain Sci* 2000; 23: 371–98.
- Pierce K, Muller RA, Ambrose J, Allen G, Courchesne E. Face processing occurs outside the fusiform ‘face area’ in autism: evidence from functional MRI. *Brain* 2001; 124: 2059–73.
- Piven J, Arndt S, Bailey J, Havercamp S, Andreasen NC, Palmer P. An MRI study of brain size in autism. *Am J Psychiatry* 1995; 152: 1145–9.
- Piven J, Arndt S, Bailey J, Andreasen N. Regional brain enlargement in autism: a magnetic resonance imaging study. *J Am Acad Child Adolesc Psychiatry* 1996; 35: 530–6.
- Piven J, Saliba K, Bailey J, Arndt S. An MRI study of autism: the cerebellum revisited. *Neurology* 1997; 49: 546–51.
- Pletnikov MV, Rubin SA, Vogel MW, Moran TH, Carbone KM. Effects of genetic background on neonatal Borna disease virus infection-induced neurodevelopmental damage. I. Brain pathology and behavioral deficits. *Brain Res* 2002; 944: 97–107.
- Rapin I, editor. *Preschool children with inadequate communication: developmental language disorder, autism, low IQ*. London: MacKeith Press; 1996.
- Reiss AL, Abrams MT, Singer HS, Ross JL, Denckla MB. Brain development, gender and IQ in children. A volumetric imaging study. *Brain* 1996; 119: 1763–74.
- Schnack HG, Hulshoff HE, Baare WF, Viergever MA, Kahn RS. Automatic segmentation of the ventricular system from MR images of the human brain. *Neuroimage* 2001; 14: 95–104.
- Sears LL, Vest C, Mohamed S, Bailey J, Ranson BJ, Piven J. An MRI study of the basal ganglia in autism. *Prog Neuropsychopharmacol Biol Psychiatry* 1999; 23: 613–24.
- Singh VK, Warren RP, Odell JD, Warren WL, Cole P. Antibodies to myelin basic protein in children with autistic behavior. *Brain Behav Immun* 1993; 7: 97–103.
- Sparks BF, Friedman SD, Shaw DW, Aylward EH, Echelard D, Artru AA, et al. Brain structural abnormalities in young children with autism spectrum disorder. *Neurology* 2002; 59: 184–92.
- Tabachnick BG, Fidell LS. *Using multivariate statistics*. 4th ed. Boston (MA): Allyn and Bacon; 2001.
- Talairach J, Tournoux P. *Co-planar stereotaxic atlas of the human brain*. Stuttgart: Thieme; 1988.
- Woodhouse W, Bailey A, Rutter M, Bolton P, Baird G, Le Couteur A. Head circumference in autism and other pervasive developmental disorders. *J Child Psychol Psychiatry* 1996; 37: 665–71.
- Yakovlev PI, Lecours A-R. The myelogenetic cycles of regional maturation of the brain. In: Minkowski A, editor. *Regional development of the brain in early life*. Oxford: Blackwell Scientific Publications; 1967. p. 3–70.
- Zhang K, Sejnowski TJ. A universal scaling law between gray matter and white matter of cerebral cortex. *Proc Natl Acad Sci USA* 2000; 97: 5621–6.

Received June 6, 2002. Revised September 2, 2002.

Second revision November 28, 2002.

Accepted December 6, 2002